

CHAPTER 1

General considerations and anaesthesia

1.1 Pre-operative assessment	1	1.6 Pre-medication and sedation	16
1.2 Instrumentation	5	1.7 General anaesthesia	20
1.3 Asepsis	7	1.8 Local analgesics	25
1.4 Sutures and suturing	10	1.9 Regional analgesia	28
1.5 Restraint	14		

1.1 Pre-operative assessment

Introduction

The bovine patient is a stoical animal and modern crushes and physical restraint options allow many techniques to be carried out in the field. However, this should not excuse a thorough **clinical** and **ethical** assessment prior to any surgical procedure.

Assessment should include numerous factors apart from the physical condition of the subject:

- welfare implications of the procedure
- potential duration of a productive life
- economic situation including insurance status and economic return on the surgery
- surgical risk regarding complete recovery
- future breeding prospects including heritability of the condition being corrected
- pathology of other body systems directly or indirectly related to the primary condition

General physical examination is essential before emergency or elective surgery to assess risks and concurrent disorders.

Welfare and quality of life

Animal welfare may be judged using a number of criteria. Making these judgements is an essential part of the vet's role. Vets must also lead by example. Decisions to perform surgery, and how it is to be done, are complex. Foremost in the process must be the welfare of the cow or calf. The surgeon should ask themselves:

- How necessary is this procedure: will benefits to the animal outweigh any pain or discomfort?
- What will the animal's quality of life be afterwards? Is the procedure likely to lead to a 'life worth living' or preferably 'a good life' for the animal in question?
- How does this procedure compare with an alternative option of humane slaughter or euthanasia?
- To what extent can pain and discomfort be mitigated during and after the procedure?
- To what extent can fear and distress be mitigated during and after the procedure?
- What can we learn from this situation to make life better for cows and calves in the future?

The last question is vital: sometimes it is easy for the surgeon to focus on the individual animal in question (that is important too) but lose sight of the greater picture. For example: performing surgery on a cow with toe necrosis can greatly improve her quality of life, but what measures can be put in place to prevent further cases? You are asked to dehorn or castrate some yearling cattle: could it be done at a younger age next time?

Warning

Some procedures are deemed to be simply unethical and there is legislation in place preventing them, though there are regional variations. Examples in the UK of illegal procedures include:

- tail docking in calves or adult cattle (except in cases of injury)
- castration over one week by means of an elastrator
- castration without anaesthetic for animals over two months of age

Furthermore, the Veterinary Surgeons Act means that any surgery involving entering a body cavity (e.g. joint spaces; abdomen; thoracic cavity) can only be carried out by a qualified veterinary surgeon in the UK. It is incumbent on the vet to provide suitable anaesthesia and analgesia.

Anaesthesia techniques are described in Section 1.7–1.9. Peri-operative analgesia is discussed in Section 2.11, though there is clearly overlap in these two areas of pharmacology and surgical preparation. The use of a crush/squeeze chute should never replace adequate analgesia and sedation for surgical procedures.

Tip

Learn and practice good communication techniques. Effective communication between farm vet and producer is vital to ensure that pain and suffering are reduced to a minimum among stock. Vets should be the leaders in animal welfare: this leadership requires exact personal skills, which is in addition to any technical abilities or scientific knowledge required of vets.

Laboratory tests

Under farm practice conditions laboratory tests may not be performed, but major parameters very simply estimated with minimal apparatus are:

- packed cell volume: microcentrifuge, microhaematocrit apparatus
- total protein: refractometer

Normal haematological and biochemical parameters of cattle are listed in Table 1.1.

In some abdominal conditions (abomasal torsion or volvulus, intestinal obstruction) estimation of plasma electrolytes (e.g. chloride) is valuable in assessing prognosis and calculating requirements for fluid replacement. Fluid therapy is discussed in Chapter 2.

Congenital defects

Incidence of congenital defects in cattle is 0.2–3%, with 40–50% born dead. Most defects are visible externally. Congenital defects reduce the value of affected calves and economic losses are most severe when combined with embryonic or foetal mortality, particularly if it results in an extended subsequent calving interval. Close collaboration between the vet, farmer and geneticist is essential and good breeding records are vital.

Tip

'Congenital' is not synonymous with 'heritable' or 'genetic'. Where it is likely that the condition is inherited, steps should be taken (e.g. castration, sterilisation) to avoid breeding from such stock. As it is not always easy to know if a congenital defect is heritable, a precautionary approach is best.

Table 1.1 Reference ranges (haematology and plasma biochemistry) in cattle.

	Units	Average (%)	Range (\pm 2SD)
<i>Haematology</i>			
Erythrocytes	$\times 10^{12}/l$	7.0	(5–10)
Haemoglobin	g/dl	11.0	(8–15)
PCV (haematocrit)	l/l	35.0	28–38
Fibrinogen	g/l	4.0	(2–7)
Leucocytes	$\times 10^9/l$	7.0	(4–12)
Neutrophils (non-segmented bands)	$\times 10^9/l$	0.02 (0.5%)	0–1.12 (0–2%)
Neutrophils (segmented mature)	$\times 10^9/l$	2.0 (28%)	0.6–4 (25–48%)
Lymphocytes	$\times 10^9/l$	4.5 (58%)	2.5–7.5 (45–75%)
Monocytes	$\times 10^9/l$	0.4 (4%)	0.02–0.8 (2–7%)
Eosinophils	$\times 10^9/l$	0.65 (9%)	0–2.4 (0–20%)
Basophils	$\times 10^9/l$	0.05 (0.5%)	0–0.2 (0–2%)
Neutrophil: lymphocyte ratio	—	0.45 : 1	—
<i>Plasma biochemistry</i>			
Urea	mmol/l	4.2	2.0–6.6
Creatinine	$\mu\text{mol}/l$	100	44–165
Calcium	mmol/l	2.5	2.0–3.4
Inorganic phosphate	mmol/l	1.7	1.2–2.3
Sodium	mmol/l	139	132–150
Potassium	mmol/l	4.3	3.6–5.8
Chloride	mmol/l	102	90–110
Magnesium	mmol/l	1.02	0.7–1.2
Total protein	g/l	67	51–91
Albumin	g/l	34	21–36
Globulin	g/l	43	30–55
Glucose	mmol/l	2.5	2.0–3.2
Alkaline phosphatase	iu/l	24	20–30
AST SGOT	iu/l	40	20–100
ALT SGPT	iu/l	10	4–50
Lactate dehydrogenase (LDH)	iu/l	700	600–850
Bilirubin	$\mu\text{mol}/l$	4.1	0–6.5
Cholesterol	mmol/l	2.6	1.0–3.0
Creatine phosphokinase	mmol/l	3.0	0–50

The above values refer to healthy adult (> 3 years old) cattle, and have been compiled from various sources. Interpretation of possible deviations from the above ranges should consider variations due to the laboratory technique, breed, lactational and nutritional status, and should always be related to the presenting signs and symptoms of the individual or group. Units are given as SI units

A limited number of conditions can be corrected surgically.

Examples of the more common defects of each body system are:

- **skeletal:** single and isolated defects include spinal abnormalities such as scoliosis, kyphosis, tibial hemimelia, polydactyly, syndactyly
- **systemic skeletal defects:** chondrodysplasia (dwarfism), osteopetrosis
- **joint defects:** arthrogryposis and congenital muscle contracture ('ankylosis'), hip dysplasia, bilateral femorotibial osteoarthritis
- **muscular:** arthrogryposis, congenital flexed pastern and/or fetlocks, muscular hypertrophy, spastic paresis
- **CNS:** internal hydrocephalus, spina bifida, Arnold Chiari malformation (herniation of cerebellar tissue through *foramen magnum* into cranial cervical spinal canal), cerebellar hypoplasia, cerebellar ataxia, spastic paresis, spastic syndrome
- **skin:** epitheliogenesis imperfecta, entropion
- **cardiovascular:** ventricular septal defect, patent *ductus arteriosus*
- **digestive:** atresia of ileum, colon, rectum and anus
- **hernias:** umbilical, scrotal/inguinal, schistosomus reflexus
- **reproductive:** testicular hypoplasia, intersex (hermaphrodite and free-martin), ovarian hypoplasia, rectovaginal constriction (Jerseys) and prolonged gestation

Many of the above musculoskeletal defects (e.g. muscular hypertrophy or double muscling in the Belgian Blue) can give rise to dystocia.

Surgical correction of several of these defects is considered elsewhere: umbilical hernia (see Section 5.13), rectal and anal atresia (see Section 5.15) and spastic paresis (see Section 9.27).

1.2 Instrumentation

A good worker needs good tools. Maintain instruments in good condition and store in sterile surgical packs for the common procedures (caesarean section, laparotomy and teat surgery).

Sterilisation

Instrument sterilisation methods include the following (the first two are recommended) (see Tables 1.2. and 1.3):

- **autoclaving** by pressurised steam, 750 mm/Hg at 121 °C for 15 minutes or at 131 °C for three minutes for non-packed instruments, or for a shorter time in high vacuum or high pressure autoclaves; 30 minutes for packs at 121 °C or 18 minutes at 134 °C.
- **gas sterilisation** by ethylene oxide followed by air drying for several days to avoid diffusion of residual gases from the materials into animal tissues.

Table 1.2 Suitability of various surgical materials for sterilisation.

	Dry heat	Autoclave	Boiling water	Ethylene oxide	Liquid chemicals
PVC (e.g. endotracheal tubes)	no	yes	yes	yes	doubtful
Polypropylene (e.g. connectors)	no	yes	yes	yes	yes
Polyethylene (e.g. catheters, packing film)	no	no	yes*, no [†]	yes	yes
Nylon (e.g. i.v. cannulae)	no	yes	yes	no	doubtful
Acrylic (e.g. perspex)	no	no	doubtful	yes	yes
Silicon rubber	yes	yes	yes	yes	doubtful

* high density,

† low density

Some acrylic plastic materials, polystyrene and certain lensed instruments may be damaged during this process.

- **cold (chemical) sterilisation** in commercially available solutions (e.g. containing glutaraldehyde). Prolonged immersion is necessary. Most equipment that is safe for immersion in water is safe for immersion in 2% glutaraldehyde. After the proper immersion period, instruments should be rinsed with copious amounts of sterile water.
- **simple boiling** of instruments: a poor, slow and tiresome means of reduction of infectious agents likely to cause damage. The minimal period of boiling is 30 minutes, longer at altitudes over 300 m. Addition of alkali to the steriliser increases bactericidal efficiency and boiling time may be safely reduced to 15 minutes. Corrosion is avoided by the addition of 0.5–1% washing soda (Na_2CO_3). Accumulation of lime in serrations or joints is removed by leaving instruments in 5% acetic acid overnight and then brushing off.

Table 1.3 Efficiency of different methods of sterilisation.

	Bacteria	Dry spores	Moulds	Fungi	Viruses
Autoclaving	+	+	+	+	+
Gas sterilisation	+	+	+	+	+
Chemical antiseptics	+	—	+	(+)	+
Boiling	(+)	—	(+)	(+)	(+)

Abbreviations: + = effective; (+) = limited efficacy; — = not effective

Warning

Ethylene oxide and glutaraldehyde are carcinogenic: environmental and safety hazards associated with these chemicals are numerous and severe.

Basic instruments for caesarean section or laparotomy

The following is a suggested list of equipment to cover most eventualities (see Figure 1.1):

- towel clamps (Backhaus) × 4, 8.8 cm
- haemostatic forceps (Spencer Wells) × 4 straight 15.2 cm, (Criles) × 2 curved 14 cm, (Halsted) × 2 mosquito straight 12.7 cm
- scalpel handle (Swann-Morton[®] or Bard-Parker[®]) × 2, P (no. 4, blades no. 22, or handle no. 3 and blade no. 10)
- rat tooth dissecting forceps (Lane) 15.2 cm
- plain dissecting forceps (Bendover) 15.2 cm
- straight scissors (Mayo) 16 cm
- needle holder (McPhail's or Gillies), right- or left-handed 16 cm
- Allis tissue forceps × 4, 15 cm
- sterile nylon calving ropes for caesarean section × 4
- embryotomy finger knife (for incision into the uterine wall, which cannot be brought near the body wall)

Also needed are suture needles. Two each of the following types and sizes are recommended (see Figure 1.2):

- 3/8 circle cutting-edged 4.7 cm and 7.0 cm
- 3/8 circle round-bodied (taper cut) 4.5 cm
- 1/2 circle cutting-edged 4.6 cm
- 1/2 curved cutting-edged 6.7 cm
- swaged-on curved round-bodied needle 4.5 cm
- intestinal straight round-bodied (Mayo) 6.2 cm
- straight cutting-edged (Hagedorn) 6.3 cm
- double-curved post-mortem needle 12.5 cm

1.3 Asepsis

Surgery involving regions where adequate skin preparation is feasible (i.e. with avoidable microbial contamination of tissues or sterile materials) should be performed under aseptic conditions. Instruments and cloths should be sterile.

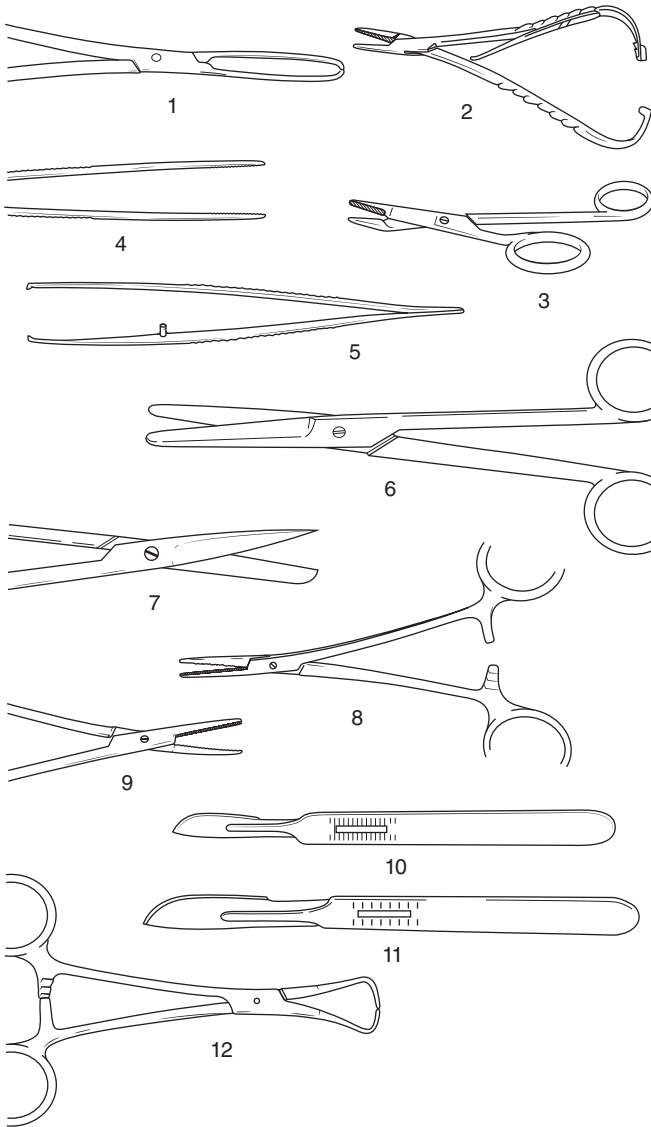


Figure 1.1 Basic instruments for caesarean section or laparotomy.

1. Allis tissue forceps; 2. McPhail's needle holder; 3. Gillies combined scissors and needle holder; 4. plain forceps; 5. rat tooth forceps; 6. Mayo scissors (blunt/blunt), slightly curved; 7. Mayo scissors (pointed/blunt), straight; 8. straight haemostatic forceps; 9. curved haemostatic forceps; 10. scalpel handle no. 4 and no. 22 blade; 11. scalpel handle no. 3 and no. 10 blade; 12. towel clip (Backhaus).

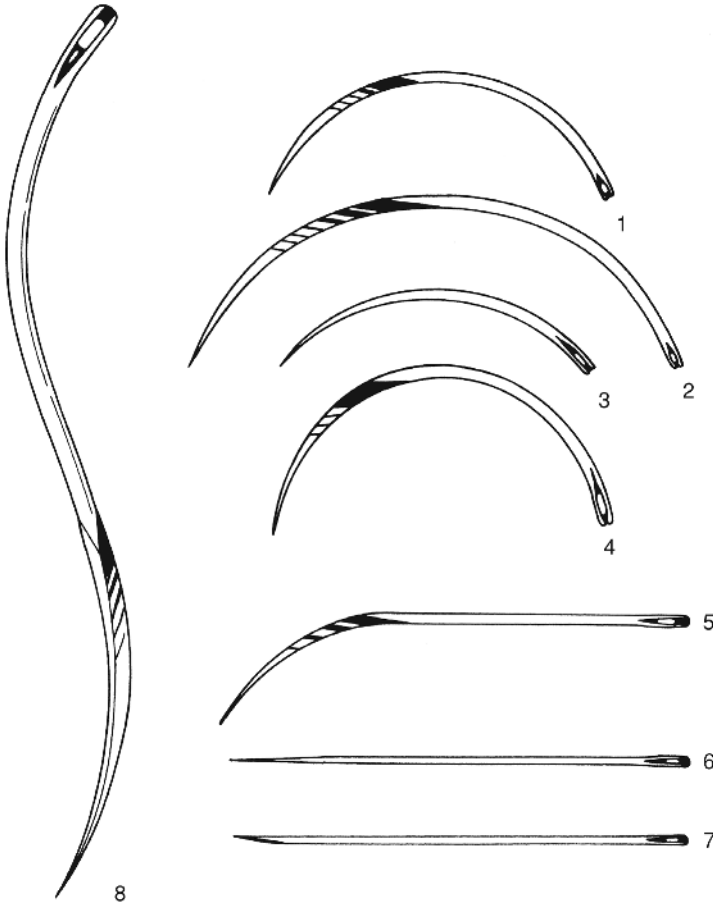


Figure 1.2 Suture needles (shown full scale).

1 and 2. 3/8 circle cutting-edged 4.7 and 7 cm; 3. 3/8 circle round-bodied (taper cut) 4.5 cm; 4. 1/2 circle cutting-edged 4.6 cm; 5. 1/2 curved cutting-edged 6.7 cm; 6. intestinal straight round-bodied (Mayo) 6.3 cm; 7. straight cutting-edged (Hagedorn) 6.3 cm; 8. double-curved post-mortem needle 12.5 cm.

Preparation of operative field

This example is for the flank:

- close clip wide area, minimum 60 cm cranial-caudal and 90 cm vertically (preferable to shaving)
- alternatively shave operative field after application of disinfectant, soap and water (Schick razor is suitable)

- wash area with soap and water twice, then scrub with povidone-iodine solution or 4% chlorhexidine gluconate, dry off, wash with 70% alcohol and rescrub
- repeat this procedure three times before respraying with diluted povidone-iodine solution or chlorhexidine solution
- large impervious sterile towels or disposable drapes (rubber or plastic) are useful for placing on the site
- place sterile towel on suitable flat surface for instruments, use sterilised gauze swabs, instruments and suture materials, and sterile gloves

Tip

Using sterile isotonic saline instead of alcohol for rinsing after scrubbing with chlorhexidine is preferable as it does not reduce the long-term effect of chlorhexidine. Never mix povidone-iodine with chlorhexidine solution.

Hand disinfection

For 'scrubbing up', effective hand and forearm sterilisation procedures include (see Table 1.4):

- commercial chlorhexidine 'scrubs'
- 0.5% chlorhexidine concentrate in 90% ethyl alcohol with 1% glycerine as emollient (cheapest)
- commercially available povidone-iodine soaps
- hexachlorophane suspension (requires a full rinse-off after a 5 minute scrub)
- 10 ml is first applied to clean dry hands and permitted to dry, before further application and a 5 minute scrub-up. At least five minutes contact time is required for all disinfectants
- sterile surgical gloves should be worn whenever practicable after scrubbing up

1.4 Sutures and suturing

Suture materials are constantly being improved and new products come on to the veterinary market at regular intervals (see Table 1.5). This section selects a limited number of materials and methods of usage, and attempts to justify the selection. In few cases can the cost of the material be considered an important factor in selection.

Table 1.4 Properties of three common antiseptic compounds.

Generic name	Povidone-iodine	Chlorhexidine gluconate or acetate	Benzalkonium chloride
Bactericidal	+	+	(+)
Fungicidal	+	+	+
Virucidal	+	—	—
Dilution for instruments	undiluted (5%, 7.5% or 10%)		10% diluted 1:500
Skin ('scrub')	undiluted (0.75%)	4% or 15 ml of 7.5% solution + 485 ml of 70% alcohol	10% diluted 1:100
Wound lavage	0.1%	0.05%	—
Disadvantages	brown skin when dry	incompatible with soap and anionic detergents	incompatible with soap and anionic detergents; fails to kill spore-bearing organisms
Advantages	not inactivated by organic matter	not inactivated by organic matter	—

Abbreviations: + = active; (+) = limited activity; — = no activity

Suture materials

Non-absorbable suture materials:

- monofilament nylon (e.g. Ethilon®): skin
- monofilament polypropylene (e.g. Prolene®): skin
- pseudomonofilament polyamide polymer (e.g. Supramid®): skin
- mono- or multifilament surgical steel: skin, bone; exceptionally *linea alba*

Absorbable suture materials:

- chromic catgut: subcutis, muscle, peritoneum, bowel, urinary bladder, uterus, penis
- multifilament polyglycolic acid or PGA (e.g. Dexon®): bowel, muscle including teat intermediate layer
- multifilament polyglactin 910 (Vicryl®): subcutis, muscle including teat intermediate layer, bowel, urinary bladder
- monofilament polyglyconate (e.g. Maxon®): subcutis, bowel, teat intermediate layer, urinary bladder, uterus

Table 1.5 Comparative qualities (graded undesirable to desirable, + to +++), of nine selected suture materials for cattle.

Generic name (trade name examples)	Origin	Tensile strength	Knot security	Handling	Tissue reaction	Resistance to infection	Absorption without inflammation after tissue repair	Cost
<i>Absorbable</i>								
Chromic catgut	collagen	(+)	+	++	+++	+	+	low
Coated braided PGA (PGS), (Dexon Plus®)	glycolic acid polymer, coated surfactant	++(+)	++	++(+)	++	++	++	high
Polydioxanone monofilament (PDS)	polymer of paradioxanone	+++	++	++	+	+++	+	high
Coated braided Polyglactin 910 (coated Vicryl®)	glycolic-lactic acid copolymer	++(+)	++	+	++	++	++	high
Monofilament polyglyconate (Maxon)	copolymer of glycolic acid and trimethylene	+++	++		+	+++	+	high
<i>Non-absorbable</i>								
Polypropylene monofilament (Prolene, Surgelene®, Proldek®)	polymerised polyolefin hydrocarbons	+++	(+)	+(+)	(+)	+++	NA	low
Surgical steel	alloy of iron	+++	+++	+	+	+++	NA	low
Monofilament nylon (Dermalon®, Ethilon, Surgidek®)	polyamide filament	++(+)	+	+	+	+	NA	low
Polyfilament polyamide polymer (Suprylon®, Vetafil®, Braunamid®)	polyamide polymer	++(+)	++	+++	+	++	NA	low

NA = not applicable

- monofilament polydioxanone (PDS): bowel, muscle, *linea alba*
- 'soft' gut (Softgut®): muscle, bowel, teat intermediate layer

Tip

Suture patterns are discussed under the specific procedures. Skin under considerable or potential tension at certain sites, such as the vulval lips and peri-anal region (e.g. following replacement of prolapsed cervix or rectum), is usually sutured with sterile woven nylon tape 3–5 mm in diameter.

Discussion

Selection of suture material should be based on the known biological and physical properties of the suture, wound environment and tissue response to the suture.

- **Monofilament nylon** remains encapsulated in body tissues when buried, but the inflammatory reaction is minimal. It has a great size-to-strength ratio and tensile strength. It is somewhat stiff and is therefore not particularly easily handled, an important point when operating in sub-optimal conditions of poor light and awkward corners. Knot security is only fair.
- **Multifilament polyamide polymer**, encased in an outer tubular sheath (pseudomonofilament), has good strength and provokes little tissue reaction unless the outer sheath is broken, but it loses strength when autoclaved. It is therefore usually drawn from a sterile spool as and when required. It is very easily handled.
- **Surgical steel** has the greatest tensile strength of all sutures and retains strength when implanted. It has the greatest knot security and creates little or no inflammatory reaction. Surgical steel, however, tends to cut tissue, has poor handling and cannot withstand repeated bending without breaking. It is sometimes used in tissues that heal slowly (e.g. infected *linea alba* or bone).
- **Chromic catgut**, of the six absorbable materials listed, is still most commonly used, but synthetic absorbable material does have distinct advantages. Catgut has relatively good handling characteristics, but has disadvantages of relatively rapid loss of strength in well vascularised sites (50% in the first week) and poor knot security (tendency to unwrap and loosen when wet). The potential minute risk of the transfer of infectious prion material into food-producing

animals and hence into the human food chain has led to a ban on the use of chromic catgut in some countries (vCJD risk)

- **Multifilament polyglycolic acid (PGA)** has greater strength that is lost evenly, provoking much less tissue reaction than chromic catgut. PGA is non-antigenic, has a low coefficient of friction and therefore requires multiple throws to improve knot security, but is easily handled.
- **Monofilament polydioxanone (PDS)** is very strong, retaining its strength for many weeks (58% at four weeks), is characterised by its strong memory and has low knot security, but provokes minimal tissue reaction. *Linea alba* is best sutured with PDS.
- **'Soft' catgut** is undoubtedly the most easily handled absorbable material for delicate bowel anastomoses. Plain or soft catgut is absorbed quickly and maintains its strength for a short time.
- PDS and PGA are slowly replacing chromic catgut, which will retain its place as a general purpose material. Vicryl® in its coated form is very easy to handle and has minimal tissue reaction and tissue drag. It is stable in contaminated wounds. Polyglyconate monofilament (Maxon™) has three times the strength of Vicryl® at day 21 of wound healing.

1.5 Restraint

Introduction

Restraint is necessary for:

- administration of drugs for (a) pre-medication and sedation, (b) infiltration of local analgesic drugs and (c) induction of general anaesthesia
- examination and minor procedures carried out without sedation or analgesia/anaesthesia
- prevention of movement during surgery
- safety of operators

Restraint may involve physical manipulation of tail, head or nostrils, or involve application of halter and ropes.

Techniques

Physical restraint by a stock person includes:

- halter
- nose grip (fingers or nose tongs)
- tail elevation

- skin grip of crural fold
- calves in lateral recumbency: lifting bottom fore leg and hind leg with elbow pressure on neck

Rope restraint includes:

- hind limb elevation by a rope above the hock and round an overhead bar
- Reuff's method of casting (see Figure 1.3), employing a rope squeeze of the abdomen

Many forms of cattle crush or squeeze chute are available with an excellent head restraint, which are suitable for surgery of the head and cranial neck (e.g. tracheotomy) and of the perineum. Many are unsuitable for flank laparotomy, caesarean sections or rumenotomy, though an increasing number of manufacturers offer modified crushes to improve access to the paralumbar fossa. A veterinary practice may find it advantageous to have such a crush available for surgery on the practice premises or to be transported to the farm. Some crushes have poor facilities for the elevation and restraint of hind or fore limbs for clinical examination and digital surgery. The Wopa crush is an example of an excellent crush for digital surgery.

Warning

An essential feature of crushes or chutes is the need to release the head rapidly should the animal collapse. Asphyxiation can result, or pressure on the point of the shoulder can cause irreversible radial nerve paralysis and a 'downer cow'.

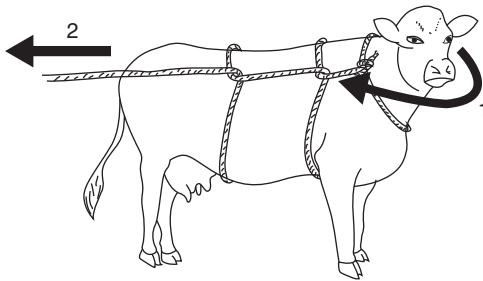


Figure 1.3 Reuff's method of casting a cow with a rope and maintaining in lateral recumbency.

The first operator (1) brings the cow's head round tightly to her right shoulder, using a halter. The second operator (2) pulls the rope so that it tightens around the cow's abdomen: this will force her to lie down. In this example the cow will go into lateral recumbency on her left side. Maintaining tension on the rope (2) will prevent her rising.

1.6 Pre-medication and sedation

Pre-medication and sedation (see Table 1.6) have six aims:

- to improve handling and restraint; improve safety
- to enhance the analgesic effect produced by other anaesthetic agents
- to reduce the induction and maintenance doses of general anaesthesia (GA) agents
- to reduce the possible disadvantageous side-effects of anaesthesia
- to promote smooth post-operative recovery
- to improve the well-being of the animal

Very few anaesthetic drugs are approved for use in farm animals. Those known to the authors include azaperone, procaine, lignocaine (lidocaine), methoxyflurane and thiamylal (USA). Xylazine is approved for use in cattle in Canada, the UK and Switzerland, and acepromazine (ACP) is also approved for

Table 1.6 Activity and dosage of selected analgesic, anti-inflammatory and sedative drugs in cattle.

Drug (example trade name)	Analgesic	NSAID	Sedative	Dosage (mg/kg)	
				i.m.	i.v.
Butylscopolamine bromide/metamizole (Buscopan® Boehringer)	+	+	–	5 ml/100 kg ^a	
Meloxicam (e.g. Metacam® Boehringer)	+	+	–	0.5 ^b	0.5
Carprofen (Rimadyl® LA soln, Zoetis)	+	+	–	1.4 ^b	1.4
Xylazine (e.g. Sedaxylan® 2%, Dechra)	+	–	+	0.05–0.3	0.03–0.1
Diazepam (Valium®)*	+	–	+	0.5–1.0	0.2–0.5
Flunixin meglumine (e.g. Finadyne®, MSD)	+	+	–	–	2.2
Ketoprofen (e.g. Ketofen® 10%, Merial)	+	+	–	3	3
Acetylpromazine* (ACP®)	–	–	+	0.03–0.1	0.03–0.1

* Not authorised for use in cattle in UK and EU, may only be given 'off label' under cascade prescribing

^a not authorised in lactating cattle

^b by s.c. route, not i.v.

use in cattle in Canada. Lignocaine is not licensed in EU countries for food-producing animals.

Although possibly not approved for use in cattle in many countries (including the USA), several non-steroidal anti-inflammatory (NSAID) analgesics (e.g. flunixin meglumine, dipyrene 50% (metamizole), ketoprofen and meloxicam) are beneficial as adjunct therapy both pre- and post-operatively in cattle with obvious somatic pain and discomfort. Pre-operative use of analgesics reduces the degree of operative discomfort and post-operative pain.

Warning

For any medication for cattle in the USA, it is the veterinarian's responsibility to consult the Animal Medical Drug Use Clarification Act for guidelines for the extra-label use of drugs and the Food Animal Residue Avoidance Databank (FARAD) for withdrawal times. Under EU legislation, the prescribing cascade can be used to prescribe 'off licence' under certain conditions and following guidelines, but additional withdrawal periods are required. UK practitioners should consult Veterinary Medicines Directorate (VMD) guidelines for cascade regulations. Only medicines that have pharmacologically active substances listed in a Table of Allowed Substances (European Medicines Agency) may be used in animals intended for food production, regardless of the cascade.

Xylazine (e.g. Rompun 2%® [Bayer]; Sedaxylan [Dechra Veterinary products])

Advantages

Very useful analgesic and sedative. Licensed for use in cattle (EU). Xylazine also causes muscle relaxation.

Disadvantages

- Causes ruminal stasis, increases salivation, uterine tone and effects of higher dose rate are somewhat unpredictable as animal may or may not become recumbent.
- Xylazine is unsuitable as the sole agent for minor surgery when more than a single painful stimulus is anticipated (e.g. unsuitable as the method of analgesia in teat surgery; lancing and drainage of large flank abscess is a suitable indication).
- Xylazine is contra-indicated in the last trimester of pregnancy due to its stimulation of uterine smooth muscle (risk of abortion). It may be used if a uterine relaxant is given before xylazine.
- Xylazine is contra-indicated in extreme heat, as hyperthermia may result.

- Avoid accidental intra-carotid injection! Violent seizures and possibly temporary collapse are likely.
- Unsuitable for placing in dorsal recumbency (e.g. certain DA surgery techniques) due to the risk of ruminal regurgitation and subsequent aspiration pneumonia.

Dosage and antagonists

- For anaesthetic pre-medication: 0.1 mg/kg xylazine i.m.
- For minor procedures in combination with local analgesia: 0.2 mg/kg i.m.
- A faster and more predictable effect is seen following i.v. 0.1 mg/kg (not authorised for all preparations).
- Xylazine sedation, analgesia, cardiopulmonary depression and muscle relaxation are reversible. Also xylazine overdosage (e.g. by inadvertent use of the equine preparation) may be antagonised by different drugs including:
 - yohimbine alone (0.2 mg/kg i.v.)
 - tolazoline (4 mg/kg i.v.) – fast onset
 - atipamazole (Antisedan® [Zoetis]) 0.02–0.05 mg/kg i.v.
 - atropine (100 mg s.c.) to counteract bradycardia and hypotension
 - doxapram HCl or doxapram 4-aminopyridine respectively 1 mg/kg and 0.3 mg/kg i.v. significantly reduces recovery period
 - mixture of doxapram (1 mg/kg i.v.) and yohimbine (0.125 mg/kg i.v.)

Tip

Doxapram acts by direct action on aortic and carotid chemoreceptors and medullary respiratory centre, while yohimbine antagonises xylazine sedation by blocking central alpha 2-adrenergic receptors. Therefore an alpha 2 antagonist such as yohimbine, tolazoline or atipamazole would be preferable to reverse accidental overdosage, though there are no licensed preparations for cattle.

Atipamazole (Antisedan®) can be given 0.025 mg/kg i.v. and 0.025 mg/kg i.m. to avoid resedation. This roughly equates to using a similar volume of 2% xylazine used but splitting it 50:50 between i.v. and i.m. routes. Overdosage can cause hyperactivity and excitement.

Chloral hydrate

Advantages

- cheap
- given orally or i.v.
- dose-dependent narcosis

- patient generally maintains a swallow reflex at usual dose rates so less risk of regurgitation/aspiration pneumonia, particularly for placing the cow in dorsal recumbency (e.g. LDA surgery or teat repair)

Disadvantages

- very irritant: can cause severe necrosis if accidental perivascular injection
- narcosis deepens after i.v. infusion: risk of over-dosage
- hepatotoxic: avoid in neonates
- not licensed
- not analgesic: local anaesthesia required in addition when used prior to surgery

Dosage

- Orally: 50–100 mg/kg as 5% solution produces recumbency and light hypnosis in adult cow in 10–20 minutes. Equivalent to 35–70 g for adult Holstein cow.
- Adult bulls require much higher oral dose: 120–160 g. Oral solutions are unpalatable even at high dilution so drenching or stomach tube is required.
- I.V. infusion: 80–90 mg/kg in 10% solution has faster effect (2–3 minutes). Give slowly i.v. (over 5 minutes) as hepatic metabolism to the active trichloroethanal causes a delay in effect.
- 50–60 g made up with water in a 500 ml bottle and administered slowly i.v. via a flutter valve gives suitable sedation for recumbency and positioning in dorsal recumbency for most adult Holstein cows.

Warning

Chloral hydrate is very irritant perivascularly. It is safer to administer i.v. using a catheter. If extravascular injection occurs, the area should be infiltrated with up to 1 litre saline. Anaesthesia should then not be attempted for at least 24 hours unless the procedure is vital and life saving.

Acetylpromazine (ACP)

- i.m. or slow i.v. injection
- variable effect in cattle but may reduce stress response; **no analgesic effect**
- causes hypotension: avoid in depressed or hypovolaemic patients
- avoid prior to GA: increased risk of regurgitation
- causes penile prolapse in bulls (variable): may be advantageous for penile examination but risk of paraphimosis if left unattended

Diazepam

- produces sedation i.v.; expensive
- more predictable effect/useful in calves (economically more viable), particularly prior to GA
- good muscle relaxation but no analgesia

Pentobarbitone

- mainly used as sedative/anticonvulsant in cases of hypomagnesaemia
- 1.5–2 mg/kg i.v. can provide effective standing sedation in adult cattle for 60–90 minutes
- avoid in calves: hepatic recycling and re-sedation likely
- **do not use preparations intended for euthanasia:** the preservatives can cause massive haemolysis

Atropine sulphate

- reduces quantity and increases viscosity of saliva
- pre-medicant dose in adult cow is 60 mg s.c.

1.7 General anaesthesia

Indications

General anaesthesia (GA) is rarely indicated in cattle. It is practised if the usual techniques of regional and local analgesia either cannot be adopted or fail. Specific indications include extensive surgery of the head, neck, chest and abdomen, or body wall, as well as most long bone fractures when maximum relaxation is desired. GA has a relative surgical indication when complete asepsis is essential, such as in umbilical hernia repair in calves. For GA, food should be withheld for 6–12 hours in calves and for up to 36 hours in adult cattle. Restriction of water is not indicated in calves and should not exceed 12 hours in adults.

Disadvantages of GA

Risks of GA in cattle include regurgitation, ruminal tympany, poor oxygenation and skeletal injury.

- (a) **Risk of regurgitation** and subsequent aspiration of ruminal contents and saliva into the trachea, bronchi and alveoli with potential lethal consequences (necrotic laryngotracheitis and necrotising broncho-pneumonia with pulmonary oedema). Endotracheal intubation is therefore *essential* to avoid this problem.

Factors affecting regurgitation include:

- depth of anaesthesia (see Table 1.7): light level provokes active regurgitation, deep level passive regurgitation
- degree of ruminal distension or tympany
- fluidity of ruminal contents
- body and head/neck position
- body movement: struggling and repositioning of animal
- volume of saliva
- duration of anaesthesia

Table 1.7 Main signs for assessing anaesthetic depth.

	Surgical anaesthesia	Excessive depth*
<i>Cardiovascular system</i>		
Heart rate and rhythm	within normal limit	bradycardia, impending arrest
Mucous membrane colour	pink	cyanotic
Capillary refill time	< 2 s	> 3 s
<i>Respiratory system</i>		
Respiratory rate	near normal	shallow, irregular, gasping, apnoea
Tidal volume	reduced	more reduced
Character	regular	irregular
<i>Ocular signs</i>		
Position and size of pupil	moderately constricted, possibly rotated down	very dilated, centrally fixed
Palpebral reflex	present	very slow or absent
Corneal reflex	present	slow
<i>Musculoskeletal system</i>		
Muscle tone (lower jaw, limbs)	moderate	poor or absent
<i>Other signs</i>		
Swallowing reflex	absent	absent
Salivary flow	present, profuse	absent
Lacrimal secretion	present	absent

* Actions to take in case of excessive depth:

- note time
- check patency of airway
- stop any volatile anaesthetic administration, give oxygen and artificial respiration
- check heart rate (for five seconds)
- check respiratory rate and character (for five seconds)
- check other vital signs (see above)

- (b) **Risk of severe ruminal tympany.** During recumbency the cardia is submerged in ruminal fluid, preventing normal eructation. Meanwhile, fermentation continues and gas builds up. Less of a problem in calves, depending on the stage of rumen development.
- (c) **Risk of severe compromise** of the effective expansion capacity of lungs as a result of:
- increased abdominal size following development of ruminal tympany causing pressure on diaphragm;
 - relatively poor oxygenation of the dependent lower lung due to inadequate circulation and pressure (ventilation–perfusion mismatch). Poorly oxygenated blood from ventral lung mixes with better oxygenated blood from upper dorsal lung, giving lowered systemic oxygenation and hypercapnia.
- (d) **Risk of skeletal injury** in induction and recovery, involving possible dislocation, myositis and nerve paralysis.
- (e) Expense and size of gaseous anaesthetic equipment and appropriate expertise in its use.

Equipment

Apparatus for GA of cattle older than three to six months is similar to that available for horses. Endotracheal intubation is essential in bovine GA. Equipment for volatile and gaseous agents is of a circle and to-and-fro pattern, incorporating a soda-lime canister and re-breathing bag with calibrated vaporiser (0–5%) to volatilise isoflurane or halothane by means of oxygen delivered by a pre-set flowmeter. The minimum internal diameter of airways in such an apparatus should be 4 cm.

Equipment for GA of calves with gaseous agents is similar to that for larger breeds of dog. The airway diameter, although theoretically inadequate, is unlikely to produce disadvantageous side-effects. Endotracheal tubes for calves should have an internal diameter of 12–16 mm, while those for adult cattle should be about 24–30 mm. Tubes of siliconised PVC are approximately one quarter the price of rubber endotracheal tubes (adult cattle).

List of equipment for GA by gaseous or volatile agents:

- anaesthetic apparatus: circle or to-and-fro system
- endotracheal tubes (calf–adult: 12–25 mm)
- syringe for inflation and clamping-off of cuff
- mouth gag (e.g. Drinkwater model)
- laryngoscope (e.g. Rowson pattern): optional for adults
- nasogastric tube to act as a guide, over which the endotracheal tube is passed (alternative)
- halothane or isoflurane and oxygen supply
- ruminal trocar and cannula

Placing the endotracheal tube in adults is best done manually using a gag to hold open the mouth. For calves, a laryngoscope with a long blade is usually necessary.

Warning

Do not use local anaesthetic lubricants on endotracheal tubes in cattle: this will anaesthetise the larynx and abate the protective laryngeal and cough reflexes. A greater risk of inhalation of regurgitated material/saliva will occur during the recovery period.

Intravenous anaesthesia (induction) agents

Intravenous agents for GA of cattle include:

- **thiopentone sodium** (no longer available in North America). Give as 10% solution by rapid i.v. injection, dose 1 g/100 kg 10 minutes after xylazine pre-medication or 1.2 g/100 kg if unpre-medicated. Perivascular injection is irritant: infiltration of 500 ml saline with hyaluronidase is essential to prevent perivascular necrosis and skin slough. 2.5% (larger volume) is safer. Catheter is advisable. Induction within 45 seconds with usually a brief period of apnoea. Duration of GA 5–8 minutes. Recover to stand in 30–60 minutes. Unsuitable for young calves < 3 months (prolonged recovery). Unsuitable for incremental doses to prolong anaesthesia
- **ketamine and xylazine**. Xylazine is given i.v. (0.1 mg/kg) or i.m. (0.2 mg/kg), followed immediately by i.m. ketamine (2 mg/kg). GA lasts for 10–20 minutes. Recovery is fairly rapid (on feet within 25–45 minutes). The two drugs may be mixed in one syringe and given i.m. (for calves: GA approximately 30 minutes and recovery in a further 90 minutes). Incremental doses (quarter or half doses of each agent) may be used successfully, but do not use ketamine on its own
- **ketamine, xylazine and guaiphenesin**. A mixture of 500 mg of ketamine and 50 mg of xylazine is added to a 500 ml bag or bottle of a 5% guaiphenesin solution. This combination is infused at 0.55 ml/kg to induce anaesthesia followed by 2.2 ml/kg/hour (adults) or 1.65 ml/kg/hour (calves) for maintenance. This combination produces good muscle relaxation and smooth recovery

After any intravenous GA technique endotracheal intubation should be carried out as soon as possible after injection. The tube should only be removed following a demonstrable cough reflex or swallowing movement. Extubation is performed with the head lower than the trunk and with the cuff inflated

until it reaches the pharynx, preventing material moving between the tube and tracheal mucosa, dribbling towards the bifurcation of the bronchi and causing a necrotic bronchotracheitis.

Immobilon™/Revivon™ is a large animal product that is a reversible neuroleptanalgesia (narcosis) with analgesia for restraint and surgical procedures with LA Immobilon, the active principle of which is etorphine, combined with acetylpromazine. It is not licensed for use in cattle, but is sometimes used in exceptional circumstances where other methods of restraint are considered too hazardous. The drug is extensively used in various species in tropical Africa, but rarely now in the UK except for restraint of dangerous animals, e.g. a bull or steer amok in public places.

Warning

Immobilon is highly toxic, causing dizziness, nausea, pinpoint pupils, rapidly followed by respiratory depression, hypotension, cyanosis, loss of consciousness and cardiac arrest.

Etorphine can be life-threatening to the operator if absorbed by any route, including through skin or mucous membranes. Extreme care should be taken. Before any use of Immobilon the appropriate dose of the antagonist Revivon (contained in the same pack) should be drawn up first into a second syringe connected to a second sterile needle, which should then be kept close at hand for immediate intravenous use in the event of an accident. A second competent person should always be instructed clearly beforehand what action should be taken with the reversing agent, which should then be injected before calling medical assistance.

Indications and dosage

- Use with a dart gun (i.e. intramuscular injection) for restraint of dangerous and uncontrollable cattle.
- 0.5–1 ml Immobilon per 50 kg bodyweight i.m. by dart syringe. Cattle become recumbent some minutes later and remain immobile for about 45 minutes. Generalised muscle tremors and poor muscle relaxation are usually apparent.
- To reverse the drug an equal volume of Revivon (diprenorphine HCl) should be injected i.v. Recovery generally occurs with minimal disturbance and noise. A second half dose of Revivon may be given s.c. after the initial i.v. dose if required.

The reader should consult specialised textbooks for further details of bovine GA.

1.8 Local analgesics

The four local analgesics of greatest value today are the hydrochloride salts of lignocaine, procaine, bupivacaine and cinchocaine (see Table 1.8). In the EU, only procaine is licensed for use in cattle.

Lignocaine

In North America, lignocaine has largely replaced procaine as it has the advantages of:

- extreme stability
- more rapid diffusion (rapid onset)

Table 1.8 Properties of four local analgesic drugs (all hydrochloride salts).

Generic name (example trade name)	Lignocaine (Lidocaine®)	Procaine (Ethocaine®)	Bupivacaine (Marcain®)	Cinchocaine (Dibucaine®)
Main indications:				
<i>surface analgesia</i> %	2–10	NS	NS	0.25
<i>infiltration</i> %	0.5–1	2–3	0.25	0.25–0.5
Nerve block %	2–3	3–5	0.5	0.5
Epidural block %	2–3	3–5	0.5–0.75	0.5
Rate of diffusion	fast	slow	fast	slow
Duration of action	60–90 mins	<60 min	≈8 hours	≈8 hours
Analgesic potency	+	+	+	+++
Toxicity	+	+	+	++
Tissue irritation	low	low	low	low
Stability at boiling point	?	good	?	?
Cost (low → high: + → +++)	++	+	+++	++
Other properties	good safety margin, non- vasodilator	vasodilator, used with adrenalin	—	decomposes if mixed with alkalis

NS = not suitable

- longer duration of action
- useful surface analgesic activity on mucous membranes and cornea

It is, however, no longer authorised for cattle in the UK and EU states, as it has no MRL. See the discussion box.

Preparations:

- injectable solutions are usually 2–3%, though 1% is adequate for most uses
- often contain adrenaline at 0.002% to prolong the activity and reduce the possibility of toxic side-effects
- 1% or 2% gel with chlorhexidine gluconate solution 0.25%, or hydrobenzoates in a sterile lubricant water-miscible base
- aerosol spray (lignocaine 10%) with cetylpyridinium chloride 0.1%
- 5% cream

Discussion

There is, in the UK at least, some confusion regarding the use of lignocaine in cattle. The only licensed local anaesthetics for cattle in the UK are two products containing procaine hydrochloride 5% and adrenaline 0.002%. These are licensed only for minor surgical procedures at doses between 2 and 5 ml and have specific contra-indications for epidural anaesthesia. It therefore follows that for any procedure requiring a higher dose than 5 ml, or for epidural anaesthesia, it will be in any case necessary to prescribe under the cascade ('off-label'). Whilst this might include the use of procaine, it can also include lignocaine, including lignocaine combined with adrenaline. The usual cascade considerations, including advising appropriate withdrawal periods, apply.

The European Medicines Agency's Committee for Medicinal Products for Veterinary Use has stated that the minimum cascade withdrawal period for meat (28 days) is suitable for lignocaine, but that an extended **15 day withdrawal period for milk** should be used.

It is therefore legal to use lignocaine-containing products, licensed in other species, in bovine caesareans, DAs and epidurals, etc., under cascade rules. However, it would not be legal to use these products for disbudding and castration where volumes of 5 ml or less are sufficient. The appropriate extended withdrawal periods must be used.

Warning

Use caution with preparations containing epinephrine (adrenaline) for teat and digit surgery, due to the risk of vasoconstriction and potential tissue hypoxia and necrosis. This can also be a risk for large volume infiltration of muscle tissue.

Toxic effects from lignocaine are rarely encountered (e.g. accidental i.v. injection); they include drowsiness, muscle tremors and respiratory depression, convulsions and hypotension. In sufficient dosage, cardiac arrest will occur.

Toxicity is more likely in calves. As a general guide, administer no more than 25 ml 1% lignocaine (15 ml 2%) to a 50 kg calf.

Procaine

- procaine (novocaine) largely replaced cocaine, and has in turn been displaced by lignocaine
- may have economic advantages over lignocaine
- duration of action is shorter than lignocaine
- combined with adrenaline hydrochloride, procaine absorption is slow (N.B. vasoconstriction)
- solutions may be sterilised by boiling
- minimal tissue irritation
- metabolite para-amino benzoic acid inhibits action of sulphonamides

Bupivacaine

- marketed as Marcain® with and without adrenaline (1:4 000 000) as a 0.25, 0.5 and 0.75% (plain) solution
- analgesic potency and speed of action of lignocaine
- considerably longer ($\times 4$) duration of activity
- very well tolerated by tissues
- indicated where prolonged epidural or perineural analgesia is required
- no MRL in the EU
- costs considerably more than lignocaine
- can be toxic (cardiotoxicity) if given intravenously

Cinchocaine and Mepivacaine

- Cinchocaine (Nupercaine™, Dibucaine®) is more toxic than procaine, but concentrations for epidural block and surface analgesia are lower (0.5%)
- longer analgesia than with procaine
- drug readily decomposed by action of alkalis and therefore syringes and needles should, if not sterile, be boiled in bicarbonate-free water

- Mepivacaine 2% (Carbocaine[®]-V) solution is sometimes used for infiltration and epidural block: equivalent to lignocaine and has several hours duration of activity

1.9 Regional analgesia

Tip

Local or regional anaesthesia is most successful when combined with adequate sedation and/or restraint. See Sections 1.5 and 1.6.

Regional analgesia is the preferred method of anaesthesia for many surgical procedures in cattle. Advantages over general anaesthesia (GA) include:

- relatively simple technique
- general availability (and licensed products)
- minimal apparatus, e.g. syringe, needles and drug
- generally low risk of toxic side-effects
- safety

Analgesia of the head

Analgesia of the horn is the most common local analgesic procedure carried out in cattle and is relatively straightforward. However, innervation of the eye is more complex and requires careful analgesia.

Cornual nerve block

- sensitive horn corium is largely innervated by the cornual branch of the zygomatico-temporal division of the maxillary nerve (from cranial V)
- caudally a few twigs of the first cervical nerve make a variable contribution to innervation
- the cornual nerve leaves the lacrimal nerve within the orbit, passes through the temporal fossa and around the lateral edge of the frontal bone, covered by fascia and thin frontalis muscle. The nerve is blocked a little below the lateral ridge of the frontal crest, about halfway between the lateral canthus of the eye and the horn (bud) base (see Figure 1.4). The cornual artery and vein are close to the site of the block

Equipment:

- disposable syringe, 10 ml for adults, 5 ml for calves; 2.4 cm 20 gauge needle; 5% procaine solution (or 2% lignocaine without adrenaline, where licensed)

Technique:

- insert the needle, with syringe attached, midway along lateral edge of crest of frontal bone, directing the needle at a 30° angle through skin towards the horn base (see Figure 1.4)
- draw back plunger to ensure that the needle is not inadvertently intravascular

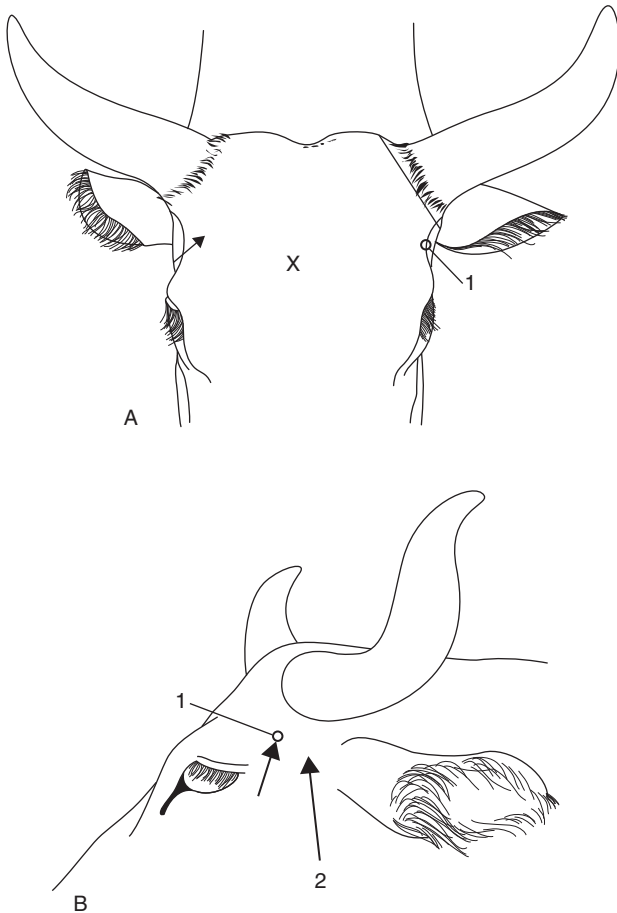


Figure 1.4 Site for corneal nerve block.

A. rostral view

B. lateral view

1 = corneal branch of zygomatico-temporal nerve. Note angle of insertion of the needle.

2 = site of auriculopalpebral block (subcutaneous)

X = site on skull for captive bolt euthanasia.

- inject solution in the arc just below the edge of frontal bone over a distance of 1 cm in adults and 0.5 cm in young calves; 2 ml per horn for small calves (≤ 50 kg), up to 10 ml per horn for adults/large calves
- repeat procedure on the other side of the head
- time to analgesia 3–5 minutes, shown by skin analgesia and upper eyelid ptosis

Complications:

- failures are due to inadvertent i.v. injection or imprecise location of the site (e.g. subcutaneous injection)
- in adults and particularly bulls, significant innervation occurs from the caudal aspect to the horn base and subcutaneous infiltration is required here in addition to a cornual block

Infratrochlear block

- exotic breeds sometimes have an additional nerve supply from the infratrochlear nerve to the medial aspect of the horns (similar to that seen in goats)
- it is blocked by subcutaneous infiltration across the forehead, transversely and level with the site of the cornual block

Tip

Debudding is less stressful for both the calf and operator when the patient is sedated. Mild sedation to accompany local analgesia can be easily achieved by adding xylazine to a bottle of local anaesthetic (4 ml 2% xylazine per 100 ml bottle of 2% lignocaine or 5% procaine) and using this local anaesthetic mixture for the cornual block in normal quantities.

Onset and duration of sedation is similar to that of analgesia. At this dose rate, calves may lie down initially but usually stand up for the debudding to be done.

Supraorbital block

Indications:

- surgery of upper eyelid
- trephination of frontal sinus

Technique:

- see landmarks in Figure 1.5. The supraorbital foramen is dorsal to the medial canthus of the eye, approximately a third of the distance from the eye to the poll (3 cm from the medial canthus in an adult cow)

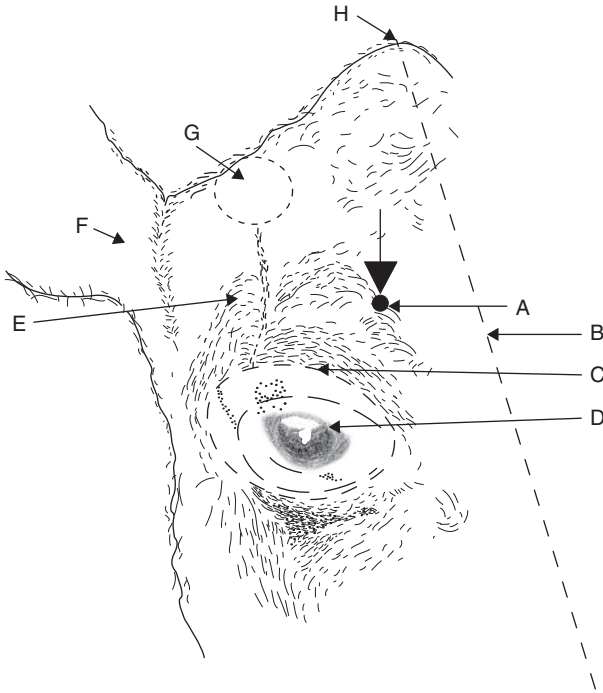


Figure 1.5 Supraorbital nerve block.

Oblique diagrammatic view of right side of head. Foramen is palpable about 3 cm dorsal to upper bony margin of orbit. Long dotted line is midline; dotted line is horn base. A. supraorbital foramen; B. median line; C. margin of bony orbit; D. orbit; E. frontal bone; F. right ear; G. horn base; H. poll.

- insert 1.1 metric (19G) 2.5 cm long needle into foramen to a depth of 1.5 cm
- inject 5 ml of 2% lignocaine or 5% procaine

Local infiltration may be used as an alternative.

Auriculopalpebral block

Indications:

- this block causes paralysis of the eyelids. Note that it produces akinesia but not analgesia
- very useful for removal of foreign bodies, eye examination or prior to subconjunctival injections

Technique:

- see Figure 1.4 for landmark. The auriculopalpebral nerve runs from the base of the ear along the facial crest. The nerve may be palpable in a notch at the end of the zygomatic ridge
- a 1.1 metric (19G) needle is inserted subcutaneously anterior to the base of the auricular muscles, just anterior to the base of the ear. The point of the needle should be at the dorsal border of the zygomatic ridge
- 5–10 ml of local anaesthetic are injected and then massaged into the surrounding area
- may be used in conjunction with topical analgesia of the eyeball (proparacaine hydrochloride, 0.5% ophthalmic solution)

Discussion**Nerve supply to ocular structures**

Innervation of ocular structures is complex:

- eyelids: motor supply – auriculopalpebral branch of facial; sensory supply – ophthalmic and maxillary branches of trigeminal
- straight and oblique muscles of eyeball: motor supply – oculomotor, abducens and trochlear
- eyeball: sensory – ciliary branch of ophthalmic
- the oculomotor, trochlear, ophthalmic and maxillary branches of the trigeminal and abducens nerve emerge from the *orbitrotundum foramen* (see Figure 1.6)

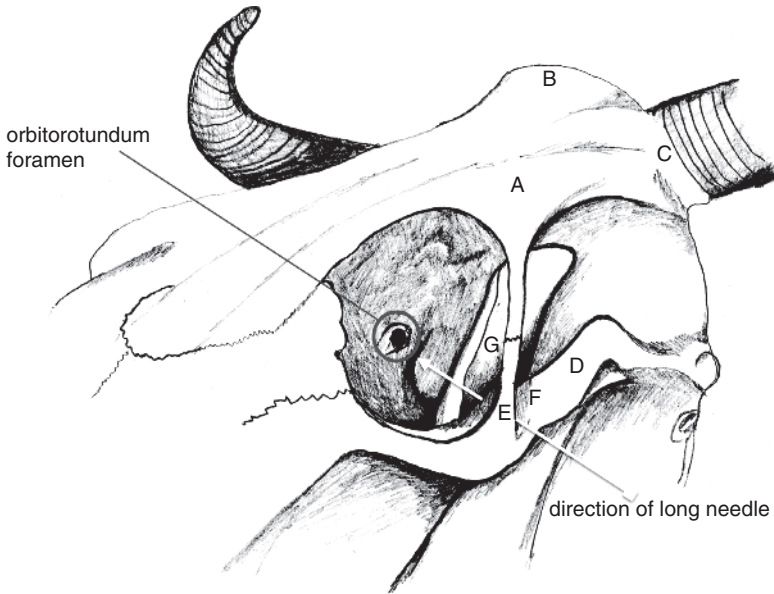
Analgesia for enucleation (e.g. squamous cell carcinoma) is by one of two methods: the retrobulbar block or Peterson's block.

Retrobulbar block**Indications:**

- intraocular neoplasia (e.g. SCC)
- severe trauma

Technique:

- produce topical analgesia of the cornea with proparacaine HCl 0.5% ophthalmic solution
- insert a forefinger into the lateral canthus between the eyeball and conjunctival sac
- alongside the finger pass a 1.25 metric (18G) 10 cm curved needle through the fornix of conjunctiva advancing along the floor of the orbit until the



A = frontal bone

B = nuchal crest (poll)

C = horn base

D = zygomatic arch

E = frontal process of zygomatic bone

F = temporal process of zygomatic bone

G = coronoid process of mandible

Figure 1.6 Bony landmarks for Peterson's nerve block.

point is retrobulbar (see Figure 1.7). The penetration of the tough periorbita should be obvious

- inject small increments of local analgesic solution as the needle is advanced
- ensure that the needle point does not enter the optic foramen (risk of intrathecal (CSF) injection) and attempt an aspiration check
- inject 20–30 ml l.a. solution beneath the periorbita, which blocks nerves to ocular muscles causing paralysis of the eyeball and analgesia
- do not attempt to anaesthetise the optic nerve, since this may stimulate the animal sufficiently to cause fatality (respiratory arrest)
- anaesthetise the upper and lower lids by local infiltration as required
- an alternative technique of retrobulbar injection is placement of 10 ml local anaesthetic at each of four sites (lateral, medial, dorsal and ventral canthi) through the conjunctiva, followed by infiltration of the eyelid margins (see Figure 1.7)

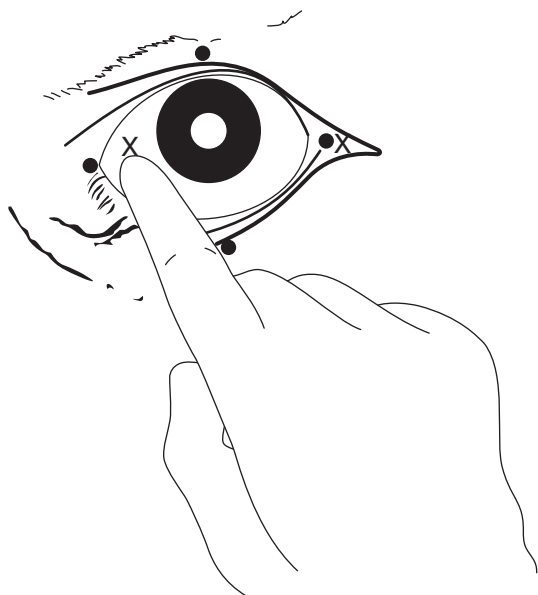


Figure 1.7 Retrobulbar block (two methods).

(a) needle insertion at four points (black circles) through eyelid and conjunctiva under careful digital guidance (4 × 8–10 ml) (b) needle insertion at lateral or medial (X) canthus, again perforating conjunctiva to deposit solution at orbital apex (20–30 ml). Use 18 gauge needle 15 cm long with marked curvature, advancing tip slowly.

Peterson's block

Technique:

- local analgesic solution is injected near the *orbitotundum foramen*, some 8–10 cm deep, located behind the eyeball. The technique requires more skill than the retrobulbar block but is probably safer (less risk of intrathecal injection)
- two needles are required: a short (2.5 cm) wide bore (12 or 14G) needle acts as a cannula for the passage of a longer (12 cm) 18G needle to the injection site
- first, inject a small amount (5 ml) of local analgesic subcutaneously at the notch formed by the supraorbital process (frontal process of zygomatic bone) and zygomatic arch (see Figure 1.6). Place the short, wide needle through the skin, as far anterior and ventral as possible
- direct the 12 cm 18G needle through the wider needle horizontally and slightly caudally. The point of the needle will make contact with bone: the anterior edge of the coronoid process of the mandible. A slight redirection rostrally will allow the needle to advance medially, off the coronoid process towards the *orbitotundum foramen*

- aspirate to check that the point of the needle is not in the large ventral maxillary artery
- inject 10–15 ml 2% lignocaine
- the technique does not block the eyelids: the needle can be withdrawn until it is just subcutaneous and redirected 5 cm caudally to block the auriculopalpebral nerve with a further 10 ml l.a. solution close to the zygomatic ridge

Tip

For Peterson's block, making a slight curve in the long narrow needle will facilitate advancement off the ventral edge of the coronoid process. Sometimes it is not possible to advance medially to the coronoid process and injection of l.a. solution at this point may still be effective.

It is useful to practise the technique on a cadaver before using for the first time.

Warning

Adverse effects of both the retrobulbar and Peterson's techniques may include haemorrhage from nearby blood vessels, direct pressure on the eyeball, penetration of the globe and optic nerve damage. These are of little consequence for enucleation but could be of considerable significance for other procedures.

Both blocks will prevent blinking for several hours so, except in the case of enucleation, it will be necessary to lubricate the cornea or suture the eyelids together for a period.

Analgesia of the flank

Mastering effective analgesia of the flank is invaluable to the bovine practitioner, for abdominal surgery including caesarean section. Most practitioners stick to the technique they first learn in early years of clinical practice. Lack of confidence often means this is the simple line block or inverse L block. We strongly recommend gaining confidence in mastering the paravertebral block as this gives distinct advantages:

- superior muscle relaxation: easier wound closure
- usually superior analgesia: better welfare
- better wound healing: no l.a. agent near to incision

Paravertebral block

Indications:

- laparotomy, omentopexy, rumenotomy, caesarean section (flank incision);
midline incision: bilateral paravertebral

Equipment:

- disposable 30 ml syringe; disposable 18G 90 mm spinal needle with stilette (dairy breeds) or re-usable 150 mm 16G needle and stilette for beef cattle; 2% lignocaine or 5% procaine with adrenalin. Total volume of solution is 100 ml (four sites)

Technique:

- block dorsal and ventral branches of spinal nerves emerging from thoracic T13, lumbar 1, 2 and 3 (T13, L1, L2, L3) by 'walking' the needle off cranial edges of L1, L2, L3 and L4 transverse processes
- best practice is to clip and scrub skin from last rib to *tuber coxae* along a band 15 cm wide, to left or right of dorsal midline as appropriate; not essential
- locate all four injection sites (see below) and put a 5 ml bleb of l.a. subcutaneously and into the dorsal epaxial muscles at each
- block nerve L3 first: identify L4 transverse process by counting forwards from the last palpable process (L5), which is just cranial to the *tuber coxae* of the ilium
- work cranially to find all four injection sites (nerve L2 = cranial edge of transverse process L3; nerve L1 = cranial edge of L2; nerve T13 = cranial edge of L1)
- correct site for each injection (in adult Holstein/Friesian cow) is 5 cm from midline, near cranial lateral edge of each transverse process (see Figure 1.8)
- wait 5 minutes for s.c. analgesia to take effect
- push needle vigorously through the skin and *longissimus dorsi* musculature, directed almost perpendicularly but with shaft inclined 10° medially
- advance needle firmly to contact and pass over cranial border of each transverse process; you may feel the needle 'popping' through the inter-transverse ligament (more difficult with a sharp, single use spinal needle and stilette) and advance 1 cm further. The needle point should now lie close to where the dorsal and ventral branches of spinal nerves have just emerged and separated adjacent to the spinal foramen
- remove the needle stilette and attach the syringe with 25 ml solution and after applying negative pressure (check needle is not in blood vessel) inject 15–20 ml solution in an area about 1 cm below the ligament, moving the shaft and needle point around very slightly
- inject the remaining 5–10 ml solution during the first stage of withdrawal of the needle above the level of the ligament to block aberrant dorsal cutaneous fibres

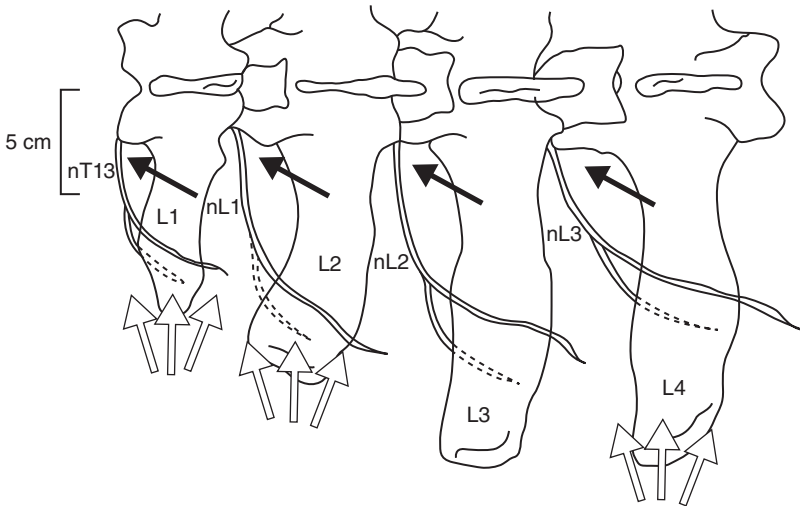


Figure 1.8 Paravertebral anaesthesia: diagrammatic view of left lumbar vertebrae 1–4 to show the course of nerves T13, L1, L2 and L3 and the position of the needle. Black arrows indicate the direction in which the vertical needle point is ‘walked off’ the transverse process (proximal technique). White arrows show the area of infiltration above and below tips of process in the distal technique.

Note: the lumbar transverse process tip, which can be palpated immediately cranially to the *tuber coxae*, is L5. It can be palpated in all but the fattest of cattle. Count forwards from this landmark. The short stumpy L1 transverse process can only be palpated in very thin cattle: its position must be estimated using the relative positions of L2, L3, L4, etc.

- the most cranial site (nerve T13) is the most difficult and least well tolerated by the patient; the distance travelled by needle shaft is usually slightly more than for preceding sites
- allow 20 minutes for analgesia to take effect; use this time to surgically prepare the operation site

Variations:

- some operators prefer to walk the needle off the caudal and cranial edges of the transverse processes. Thus, nerves T13 and L1 may be accessed from a single point above transverse process L1. However, the required needle angles would be too acute to access both nerves L2 and L3 from a single injection site over transverse process L3. It is easier to walk off the cranial edges—and easier to remember—though the nerve is actually closer to the caudal edge when injecting 5 cm from the midline

- some operators omit the initial s.c. bleb of local anaesthetic: this leads to greater discomfort of the patient and difficulty for the operator
- for more caudal incisions (e.g. caesarean) it may be possible to omit nerve T13; for cranial approaches to the abdomen, it may be possible to omit nerve L3
- the technique described above is the **proximal** paravertebral approach. The **distal** approach employs a horizontal needle insertion (see Figure 1.8). The local anaesthetic solution is deposited above and below the tips of transverse processes L1, L2 and L4 (not L3); 10–15 ml of l.a. is injected in a fan-shaped area ventral and dorsal to the transverse process tips, to a depth of approximately 3–4 cm

Field of analgesia:

Commencing analgesia is noted by a convex curvature of the spine on the injection side resulting from relaxation of *longissimus dorsi* and flank musculature. The field of analgesia runs slightly obliquely ventrally and caudally to the midline. Innervation of the individual dermatomes overlap so that a block of a single nerve produces a very narrow (1–4 cm wide) analgesic skin band over the flank. T13 innervates skin over the middle of the last 1–2 ribs (12–13), while an L3 block causes analgesia as far caudal as *os coxae*. The dorsal nerve ramus innervates the skin over the upper one third of flank skin, while the ventral ramus innervates the remainder of the flank (see Figure 1.9).

- T13: dorsocranial flank, ventrally to umbilicus
- L1 (*n. iliohypogastricus*): dorsal midflank abdominal wall
- L2 (*n. ilioinguinalis*): caudal flank skin over stifle and inguinal region, scrotum and prepuce, or udder
- L3 (*n. genitofemoralis*): caudal flank, especially ventrally, stifle, inguinal region, scrotum and prepuce, or udder

Tip

In the proximal paravertebral technique the needle may be inserted too far and enter the peritoneal cavity; there is usually a slight negative pressure, but aspiration can be used to check the needle placement (it should not be possible to aspirate).

In well conditioned cattle (particularly beef breeds), landmarks are more difficult to see and palpate. In such cases take particular care that the injection site remains close to the midline (5–8 cm) and that a long enough needle is being used to penetrate the intertransverse ligament.

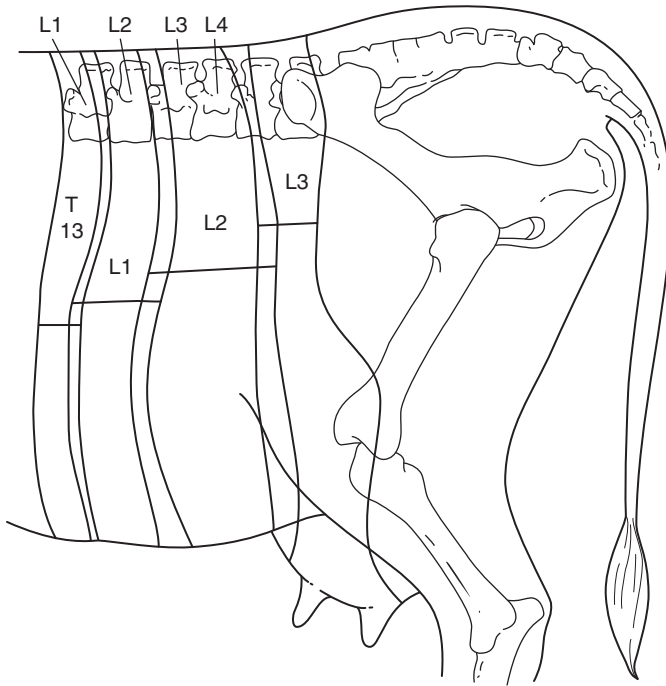


Figure 1.9 Diagram of innervation of the left flank: paravertebral anaesthesia. Horizontal bars indicate width of skin analgesia from the block of individual nerves. Note the degree of overlap of dermatomes and caudal displacement of the analgesic field relative to the particular nerve root. (Modified from Dyce and Wensing, 1971.)

Discussion

The paravertebral block is easier in cattle with a poor body condition because identifying the landmarks is easy and the required needle depth is less. The analgesic technique in exceptionally large-framed and fat cattle requires a longer needle (≥ 12 cm long). A successful block results in localised hyperthermia and moderate convexity of the spine, which, particularly with a block of L4, may cause mild ataxia.

Advantages of the paravertebral block over flank infiltration include:

- minimal volume of anaesthetic solution
- absence of anaesthetic solution in the surgical field
- large area of desensitisation
- rapid onset of action
- analgesia of peritoneum

Line block, T block or inverted L (7) pattern**Indication:**

Anaesthetic infiltration at or around the incision site can produce adequate analgesia. It can also be used following an unsuccessful paravertebral block. Its advantage is simplicity. Its disadvantages include:

- large volume of solution, local oedema and haemorrhage
- distortion of tissue layers
- poor analgesia of peritoneum
- poor muscle relaxation
- increased post-operative swelling
- increased risk of wound infection

Technique:

- infiltrate subcutaneous tissues, muscularis and the sub-peritoneal layers in three distinct movements
- insert the needle at the point where horizontal and vertical bars of imaginary 'T' join (see Figure 1.10). This point forms the dorsal commissure of intended flank incision
- pass the needle (18G 10 cm) cranially to the full extent subcutaneously, and infiltrate with 2% lignocaine or 5% procaine (without adrenaline) during slow withdrawal
- detach the syringe and, without removing the needle from the skin, direct the point caudally and advance, and likewise infiltrate during withdrawal

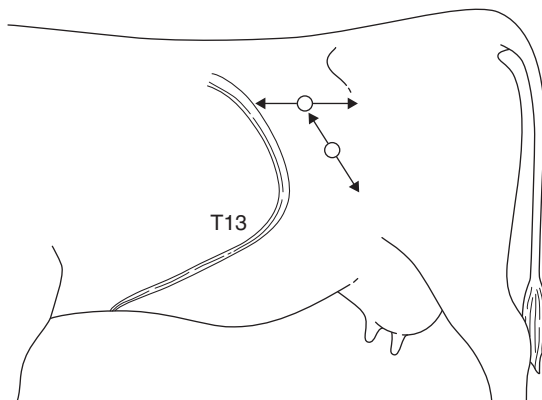


Figure 1.10 Method of infiltration of the body wall of flank in the 'T block'; the technique can also be used in 'reverse 7 block'. Note that the needle is only inserted through the skin twice in the whole analgesic procedure.

- repeat with infiltration of deeper tissues (total of about 80 ml in a horizontal line)
- insert the needle 10 cm ventral to the previous point and similarly infiltrate the proposed incision line (another 80 ml, i.e. total of about 160 ml in an adult cow)

Note that in this technique the needle is only inserted through skin twice in the entire infiltration.

Inverted L block ('reverse 7' left flank; '7' right flank)

- A slight variation in the linear infiltration of the flank is the 'reverse 7 block' or 'inverted L block', which are self-explanatory (see Figure 1.10). The nerves are blocked a little further proximally in their paths, cranially and dorsally to the incision site. This avoids some of the tissue distortion that a line block produces.

Analgesia of the pelvic and mammary regions

Epidural block

Indications:

Caudal epidural

- reduce abdominal straining and discomfort, e.g. after calving
- intravaginal and intrauterine manipulations (e.g. embryotomy), dystocia (abolishes tenesmus)
- replacement of vaginal and uterine prolapse, rectal prolapse
- perineal and tail surgery

Cranial epidural

- same site, larger volume of analgesic solution
- flank laparotomy, surgery of hind limbs and digits, penis, inguinal surgery, udder and teat surgery

An analgesic solution is injected into the epidural space, which caudally contains branches of spinal nerves (*cauda equina*) invested with epineurium (*dura mater*), small dorsal and ventral venous plexuses, and a variable amount of fatty tissue.

Equipment:

- 5 ml (caudal epidural) or 30 ml syringe (cranial)
- short bevelled 5 cm 19G needle
- 2% lignocaine or 5% procaine without adrenaline
- \pm 2% xylazine

Tip

Preparations containing preservatives, such as chlorocresol and sodium metabisulphite, and adrenaline are contra-indicated for epidural injection. In practice, many practitioners use the commercially available local anaesthetic preparations, which contain both preservative and adrenaline for caudal epidurals without adverse effects.

Technique:

- locate first intercoccygeal space (Co1–Co2), which undergoes significant movement when the tail is elevated (sacrococcygeal space is virtually immobile). It measures about 1.5 cm transversely and 2 cm craniocaudally (see Figure 1.11)
- this should be an aseptic procedure, so clip the site with scissors and disinfect. Entry of infection is a serious problem and could lead to permanent paralysis of the tail, resulting in persistent faecal contamination of the perineal skin and udder, and subsequent culling. This is a very rare complication
- insert the needle precisely in the midline, directed very slightly cranially, the shaft forming an angle of 15–20° with the vertical in a standing animal. Note that structures penetrated are skin, fat and interarcuate supraspinous and interspinous ligaments
- appreciate at a depth of about 2 cm that the point of the needle is freely movable
- inject 5 ml of lignocaine solution slowly; there should be no appreciable resistance

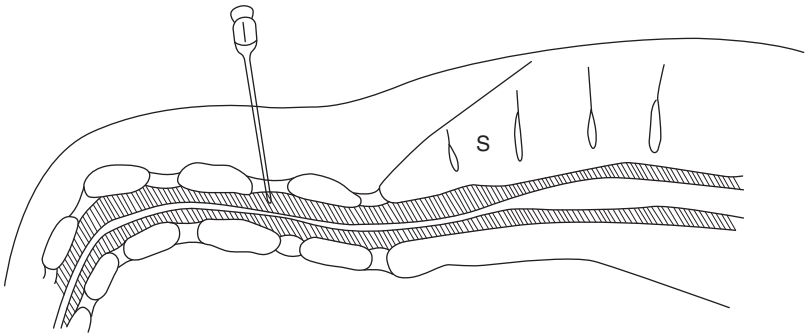


Figure 1.11 Caudal epidural block at the intercoccygeal (Co1–Co2) space. s = sacrum; shaded area is spinal canal with *cauda equina*.

- a palpable “popping” sensation may be noticed when the needle is advanced into the epidural space (less so with sharp needles)
- if resistance to injection is encountered, the needle has been inserted too deeply and has entered cartilaginous tissue of an intervertebral disc (point cannot be moved from side to side) or, though free in epidural space, needle lumen may be blocked by fibrous tissue. In either case remove the needle and repeat with a new needle
- the tail becomes flaccid within 5 minutes, which is an obvious method of ensuring a successful technique

Caudal (low) block

The dose is 5–7 ml of lignocaine or procaine in adult cows, 7–10 ml in bulls, 1–2 ml in calves (approximately 1 ml/100 kg). The field of analgesia with a caudal block extends from the tail base to ventral perineal skin and approximately 25–30 cm lateral to the midline. Increased dosage to 30 ml invariably causes severe ataxia, with recumbency in most individuals.

Cranial (high caudal) block

The dose is 40–80 ml in adult cattle, 5–25 ml in calves. The hind limb function is affected by desensitisation of L6 and sacral (S) 1 and 2 nerves (sciatic supply) L5 and L6 (obturator and femoral) and more cranial nerves. Dysfunction, depending on the degree of involvement, ranges from mild ataxia and slight spasmodic flexion and extension of stifle and hock joints to complete posterior paralysis.

Discussion

A major disadvantage of high volume epidural is the risk of injury during the onset (ataxia) or recovery phase (e.g. hip dislocation). Recovery to standing takes several hours, and the patient should not be permitted to attempt to stand until tail sensation has returned. Keep in sternal recumbency with the hind legs roped together above the hock or sedate with xylazine or acetylpromazine to prevent attempts to stand. A straw-bedded box or yard is advised.

Prior sedation may also reduce the patient's anxiety and struggling.

Factors affecting the extent of epidural block include volume, concentration of the drug, bodyweight, pregnancy and position of the cow.

Xylazine and xylazine-lignocaine/procaine combinations:

- analgesia after epidural administration of xylazine lasts more than twice as long (approximately four hours) as after an equivalent use of lignocaine or procaine alone

- a dose of 0.05–0.1 mg/kg body-weight of 2% xylazine (20 mg/ml) may be used. Dilute to total volume of 5–10 ml with sterile 0.9% saline solution or distilled water, e.g. 1.75 ml 2% xylazine in 3.25 ml saline solution for a 700 kg cow
- alternatively, use 0.02–0.03 mg/kg xylazine diluted with 2% lignocaine or 5% procaine to 5 ml total volume for an adult cow. This has the advantage of faster onset than xylazine alone and requires a lower dose, which reduces the sedation
- very useful in cows with chronic tenesmus (see Section 5.16). The extent of perineal analgesia is more variable than with lignocaine, but may include the entire perineal region, including the udder and flank
- side-effects may include marked transient sedation, hind limb ataxia, bradycardia and hypotension. These can potentially be reversed using a peripheral vasodilator without affecting analgesia. There are no such products licensed for food-producing animals in the EU

Tip

Add 0.75 ml of xylazine 2% to 5 ml of 2% lignocaine or 5% of procaine in the same syringe. This gives a suitable mixture sufficient for a long-acting caudal epidural in an adult Holstein cow. This is equivalent to approximately 0.025 mg/kg of xylazine.

Internal pudendal block**Indications:**

- penile surgery distal to sigmoid flexure
- examination of prolapsed penis in standing animal
- reducing straining after vaginal trauma
- desensitises perineal region, anus, rectum, penis, scrotum, outer lamina of prepuce (male), vagina, cervix and distal urethra (female). Does not desensitise the testes

Equipment:

- 16G 10–15 cm needle, 30 ml syringe
- 2% lignocaine or 5% procaine

Technique:

- the Larsen method involves a block of the pudendal nerve (fibres of ventral branches of S3 and S4) and anastomotic branch of caudal rectal nerve (S3 and S4) via an ischiorectal fossa approach
- scrub the perineal region clean and inject a small bleb of anaesthetic either side of the rectum

- insert a gloved hand in the rectum to locate the nerve lying on the sacrosciatic ligament immediately dorsal and lateral to the obturator foramen, which is less than a hand's breadth cranial to the anal sphincter
- note pulsation of the internal pudendal artery just ventral to the nerve
- insert the needle forward at the deepest point of ischioanal fossa, directed slightly downwards for a distance of 6 cm (see Figure 1.12)
- check the position of the needle point by rectal digital control and inject 20–25 ml solution (e.g. 2–3% lignocaine) around the nerve, spreading by massage
- withdraw the needle slightly and redirect slightly more caudally and dorsally to inject a further 10–15 ml (caudal rectal branch of the pudendal nerve)
- again, slightly withdraw before redirecting slightly cranially and ventrally to inject 10–15 ml at the cranial border of the foramen (communicating branch from the sciatic nerve)
- repeat the procedure on the other side of the pelvis, reversing the position of the hands
- allow 30–40 minutes for the block to take effect. Penile prolapse is followed by a loss of sensation

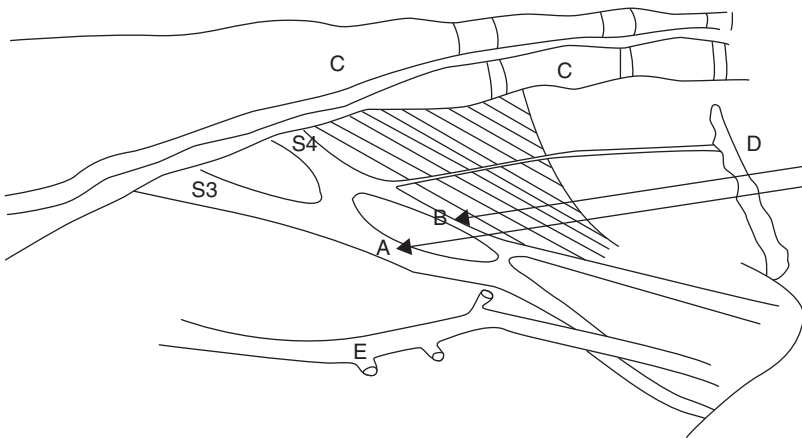


Figure 1.12 Internal pudendal nerve block. Diagram shows nerves (from sacral 3 and 4) and injection sites A and B on the medial surface of the right pelvic wall and floor of the cow (pelvic viscera removed).

A is just dorsal and lateral to obturator foramen; B is slightly more caudal and dorsal; C is the sacrum and coccygeal vertebrae 1–3; D is the anus through which the hand is inserted only to wrist level; E is the internal pudendal artery (pulsation) and lies just ventral to sites A and B.

Discussion

Manipulation of a long needle is easier if a short stout (14G 2–3 cm) needle is inserted through the skin (and analgesic skin wheal) serving as a cannula for the longer needle. Alternatively, a caudal epidural block (5 ml) rapidly desensitises the area of intended needle insertion.

The pudendal block persists for several hours. The main advantage is that the patient remains standing. The volume of l.a. necessary to block the nerve supply to the penis by an epidural technique almost invariably causes posterior paralysis. Cleanliness and experience of the pelvic landmarks are the main criteria for success with the pudendal block. Technical failures are common in inexperienced hands. A long delay (30–40 minutes) before the onset of analgesia is a further drawback.

Block of dorsal nerve of penis

The alternative technique to pudendal block for penile relaxation and analgesia involves analgesia of the dorsal nerve of the penis as it passes over the ischial arch.

Technique:

- infiltrate skin 2.5 cm from the midline adjacent to the penile body
- insert the needle, advancing to contact the pelvic floor and withdraw 1 cm (see Figure 1.13)
- check that needle is not intravascular (dorsal artery of penis)
- infiltrate 20–30 ml 2% lignocaine (plain) into region
- repeat procedure on opposite side of penis
- onset of analgesia in about 20 minutes; duration one to two hours

Intratesticular block

Technique:

- single injection of 3–5 ml l.a. into the body of each testicle prior to castration
- very fast onset (3 minutes) but short duration (10 minutes)
- achieves analgesia of the spermatic cord as well as the testicle, but the scrotal skin remains sensitive
- for open surgical castration, a small bleb of l.a. subcutaneously at the incision site may be beneficial
- aseptic technique is particularly important where bloodless castration is used

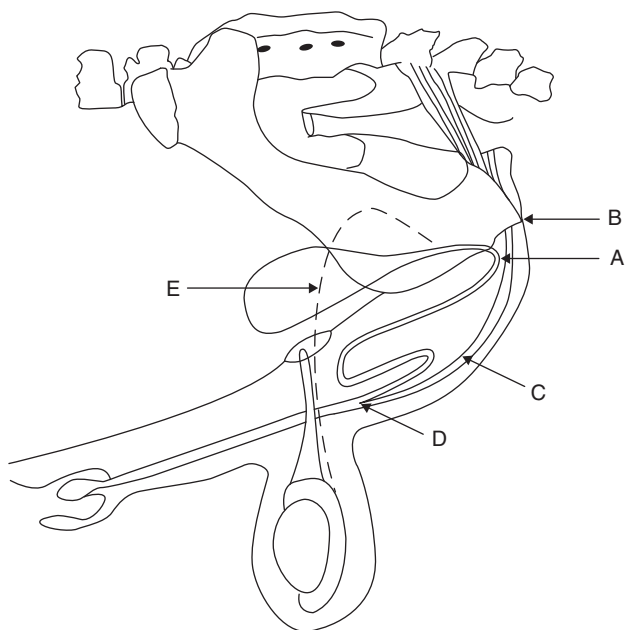


Figure 1.13 Block of dorsal nerve of the penis at the ischial arch.

A. insertion of needle horizontally 2.5 cm from midline where the penile body is palpable below the level of *tuber ischii*; B. *tuber ischii*; C. retractor penis muscles and penis; D. point of insertion of retractor penis muscles; E. *vas deferens*.

Teat block

Indications:

- teat analgesia is required for repair of teat lacerations (perforating fistula and severe lacerations), polyp removal, mucosal flaps of the rosette of Fürstenberg and supernumerary teats
- analgesia is also needed for teat endoscopy (not discussed further)

Equipment:

- 10 ml syringe, 21G 2.4 cm needle, catapult elastic and large curved artery forceps, or dog tourniquet
- 2% lignocaine or 5% procaine

Technique:

- sedate patient and lift one hind leg in the crush
- perform local infiltration of the teat base after removing any protruding hairs from the udder

- insert the needle subcutaneously transverse to the direction of the teat and make an s.c. injection of 10–20 ml l.a. solution as a peripheral (ring) block (see Figure 1.14)
- accidental injection of anaesthetic into the teat cistern or circular veins at the teat base is not harmful but is ineffective in producing analgesia
- analgesia develops in 5–10 minutes
- place the tourniquet, teat clamp or intestinal clamp (with rubbers) on the teat base to reduce bleeding and dripping of blood and milk

Discussion

Partial analgesia can be achieved by infusion of the teat cistern with 2–5 ml l.a., but is not recommended. Even cases of polyps and stenosed teat orifices prove difficult to block in this way because only the mucous membrane becomes desensitised. The intermediate layer is also involved in the surgical trauma and will remain sensitive.

Using a ring block, the entire teat is anaesthetised distal to the site of injection. An alternative technique is by i.v. injection of any superficial teat vein distal to a tourniquet. This produces analgesia throughout the teat but is virtually only possible in a recumbent cow.

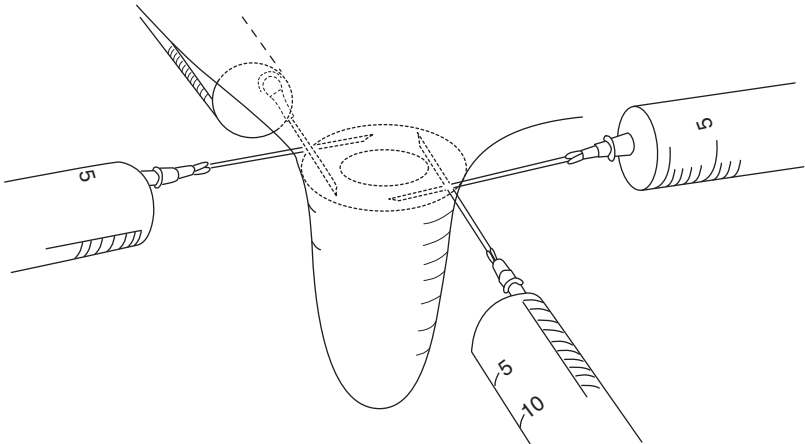


Figure 1.14 Teat ring block: 10–20 ml of 2% lignocaine or 5% procaine evenly distributed around the teat base.

Analgesia of the distal limbs

Intravenous regional anaesthesia (IVRA) of digit

This technique is simple and effective and supersedes the cumbersome local infiltration or nerve block procedures. It is indicated in any painful interference distal to the hock and carpus, and is ideal for digital surgery. No additional tourniquet is required for foot surgery on a cow in a Wopa-type crush (see Figure 1.15).

Equipment:

- If required, a tourniquet of stout rubber tubing, metal clamp to fix the tourniquet, two rolls of muslin bandages (or similar padding material)
- 30 ml syringe and 21G winged infusion set (butterfly catheter)

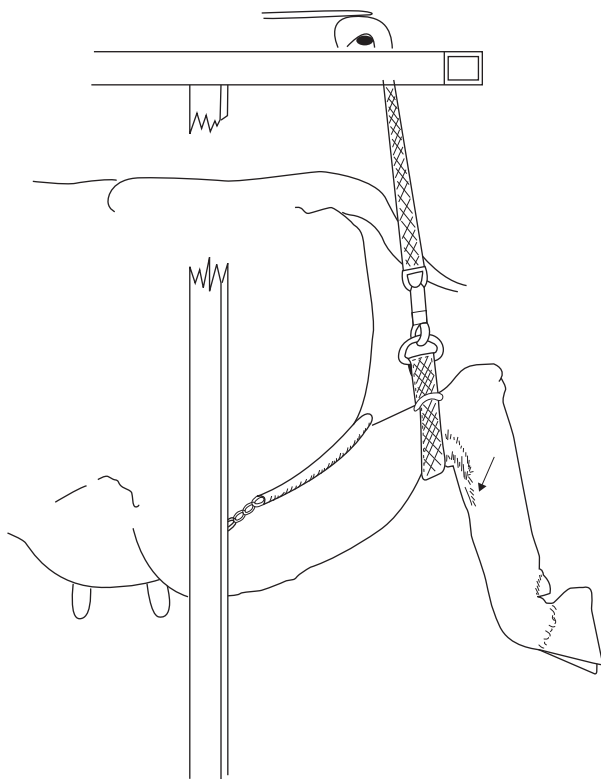


Figure 1.15 Intravenous regional anaesthesia (IVRA) in cow standing in a Wopa-type crush, using the lateral saphenous vein. The strap above the hock forms a sufficient tourniquet for this technique. Arrow shows injection site. A 19G butterfly catheter (winged infusion set) is recommended.

Technique:

Cow standing in Wopa crush (hind limb):

- elevate the limb using strap and buckle, fixed overhead (strap above hock is an efficient tourniquet)
- note lateral saphenous vein prominent in the proximal quarter of metatarsus (see Figure 1.15)
- push vein sideways to make it more prominent and relatively immobile
- place needle of a 21G winged infusion set (bung removed from the end) into the vein, aiming distally (against the blood flow); blood will quickly flow into infusion line and should be under pressure
- inject 25–30 ml of 2% lignocaine or 5% procaine quickly (adult cattle)
- analgesia develops in the entire limb distal to the tourniquet after about 5–10 minutes and is optimal after 20 minutes. Test the block with a needle-prick in the interdigital cleft
- anaesthesia persists for at least 90 minutes if the tourniquet is left in place

Cow in lateral recumbency:

- restrain animal in lateral recumbency, preferably after an i.v. or i.m. injection of xylazine for sedation, with the affected limb uppermost
- wrap the rubber tourniquet firmly around the limb proximal or distal to the hock or carpus (see Figure 1.16)
- in the hind limb place a rolled bandage in the depression on either side of the limb between the Achilles tendon and tibia to increase pressure on the underlying vessels
- clip the hair over any convenient and visible superficial limb vein distal to the tourniquet. The lateral saphenous or lateral plantar digital vein is a suitable site in the hind limb (see Figure 1.16)
- insert the needle of 21G winged infusion set, either in a proximal or distal direction, into the vein; observe for flow of blood and inject 20–30 ml 2% lignocaine or 5% procaine as rapidly as possible
- remove the needle from the vein and massage the site well for one minute to prevent development of subcutaneous haematoma

Forelimb:

- tourniquet is placed around the distal radius or proximal metacarpus
- make an injection into a superficial vein medially, e.g. large radial vein passing medially across the carpus (clipping site helps to visualise) or cephalic over the distal radius
- alternatively, use a low tourniquet (mid metacarpal region) and inject into a deep digital vein that is midline halfway between the accessory digits and the heel bulbs on the palmar aspect (see Figure 1.16). Use a 19 G 4 cm needle (observe blood before connecting a syringe and injecting).

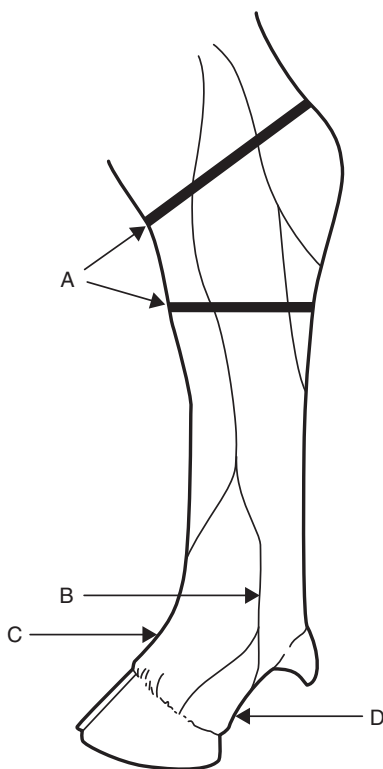


Figure 1.16 Intravenous regional anaesthesia of the hind foot–distal sites. Lateral aspect of the left hind limb of the cow showing two possible positions for a tourniquet (A) and sites for injection into the lateral digital vein (B) and dorsal common digital vein (C), lying deep, at the pastern between the proximal phalanges. A third site (D) is the deep digital vein accessed exactly midline halfway between the bulbs of the heel and the accessory digits.

Discussion

- The speed of onset is governed to some extent by the volume of the I.a. solution used, since higher intraluminal pressure causes more rapid diffusion of the solution (e.g. 30 ml versus 20 ml).
- The tourniquet may safely be left for two hours, although few surgical procedures ever require this length of time. Usually surgery is finished in 10–30 minutes, when the tourniquet may be safely released. Sensation returns within 5–10 minutes.
- Ideally the tourniquet remains in place for over 20 minutes: I.a. solution (and adrenaline) gaining access to the systemic circulation

could cause severe arrhythmias. Signs of toxicity might include drowsiness, minor convulsions and seizures, trembling and profuse salivation with hypotension. In reality, the risks appear relatively small and rarely reported, perhaps due to rapid detoxification in the liver.

- Lack of success is generally due to slackness of the tourniquet, which has failed to occlude the vascular drainage of some deeper vessels or perivascular injection. Analgesia occurs latest in the interdigital region.
- Lignocaine or procaine without adrenaline is preferred, but in practice, commercial preparations with adrenaline are usually used.
- The winged infusion set is not essential but makes the technique much easier because if the limb moves during injection of the I.a. solution, the needle is more likely to stay in place.

Warning

IVRA may be impossible to perform if there is severe swelling of the distal limb (e.g. cellulitis). In such cases, even if it is possible to locate a suitable vein, it is unlikely that sufficient intraluminal pressure of I.a. solution will be achieved. Regional nerve blocks should be used in preference.

Distal limb local anaesthesia (not IVRA)

Indications:

- distal limb surgery where IVRA fails or is not suitable (e.g. severe swelling)

Technique:

- inject 5–10 ml I.a. solution over peripheral nerves at four sites subcutaneously (depending on which digit requires anaesthesia):
 - i. two sites 1 cm distal to both accessory digits (palmar or plantar axial nerves). Block both nerves regardless of digit requiring anaesthesia
 - ii. midline dorsally just proximal to the metacarpal or metatarsal joint (dorsal common digital nerve, a branch of dorsal metatarsal/metacarpal nerve)
 - iii. for lateral claw: 1 cm proximal to an accessory digit on the lateral aspect (lateral plantar/palmar nerve)
 - iv. for medial claw: 1 cm proximal to an accessory digit on the medial aspect (medial plantar/palmar nerve)
- onset of anaesthesia in 10–15 minutes
- alternatively, a ring block (subcutaneous injection) may be used approximately 3 cm proximal to the digit to be anaesthetised